

Historical Review of Muscular Contracture Caused by Intramuscular Injections in Japan

Shoichi KOKUBUN, M. D.

Department of Orthop. Surg., Tohoku Univ. School of Medicine, Sendai, JAPAN

1. History

- 1946 Morisaki N: 1st case of quadriceps contracture
- 1965 Sato M: 1st case of deltoideus contracture
- 1970 Toyota K: 1st case of gluteus contracture
- 1973 Mass outbreak of quadriceps contracture in Yamanashi Prefecture
- 1974 Orthopaedists and Paediatricians: Volunteer Survey Group
Ministry of Health & Welfare: Committee on Quadriceps Contracture
A preliminary nationwide survey found 2,404 cases of quadriceps contracture.
- 1975 Japanese Orthopaedic Ass. (JOA): Committee on Muscular Contracture (till 1985)
Japan Paediatric Soc. (JPS): Committee on Muscular Contracture (till 1983)

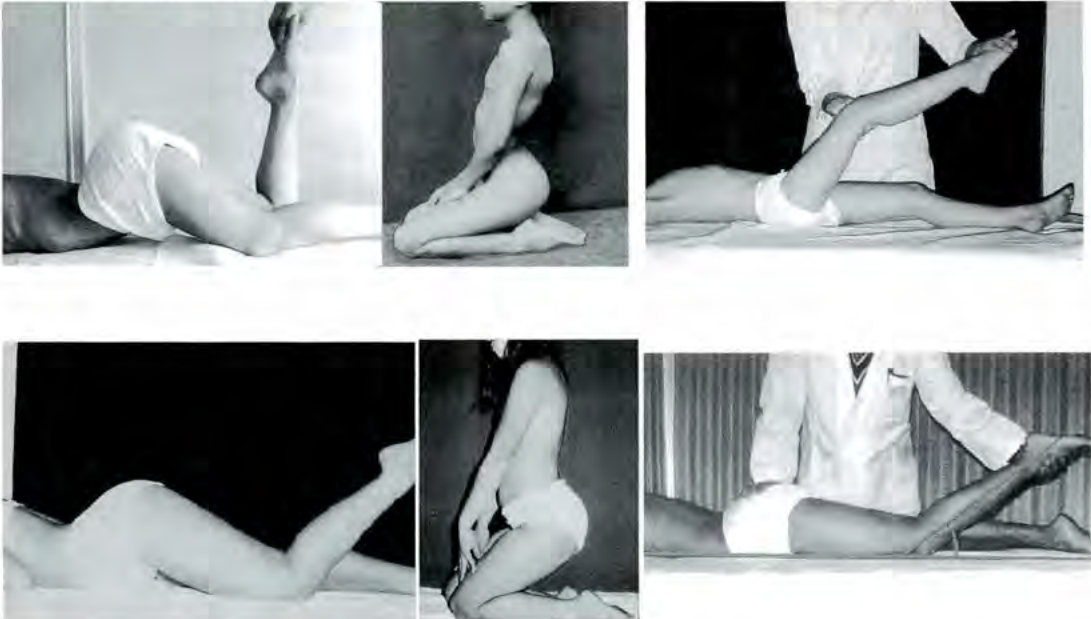
2. Advises by JPS & JOA Committees

- 1976 JPS : Guide for intramuscular injections
JOA: Criteria for diagnosis of quadriceps contracture
- 1977 JOA: Types of quadriceps contracture & their operative treatment
- 1979 JOA: Operative treatment of deltoideus & gluteus contracture

3. Quadriceps Contracture:

Rectus femoris type: 80 - 90%

Vastus type: very rare



Operative Indications & Recommended Procedures:

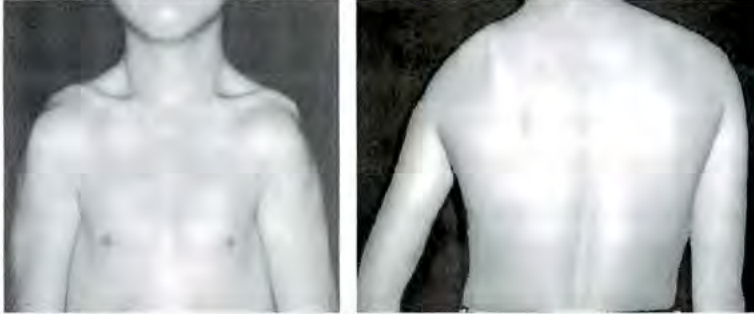Rectus femoris & Mixed types

- older than 10 years of age
- knee flexion of less than 30 degrees in prone position
- transverse section of the rectus femoris at its belly + incision to fibrotic vastus muscle fibers

Vastus type

- knee flexion of less than 30 degrees
- quadricepsplasty at the common tendon

4. Deltoid Contracture: less common than quadriceps contracture



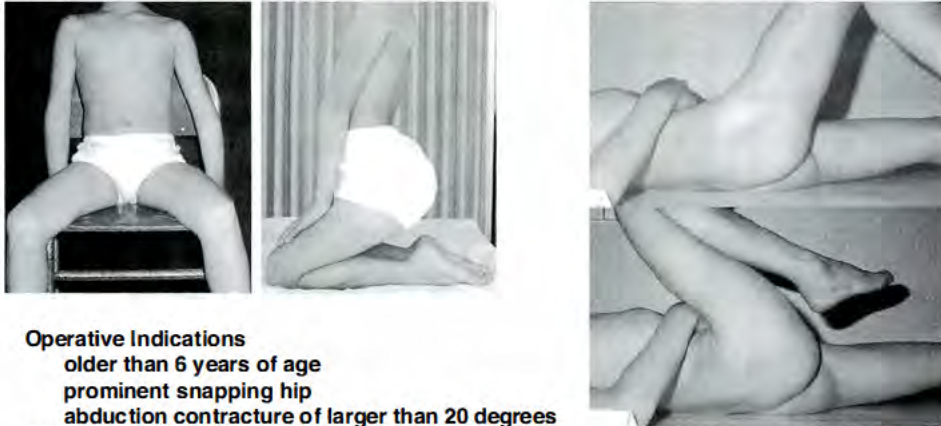
Operative Indications

- older than 12 years of age
- abduction contracture of larger than 20 degrees

Recommended Procedures

- muscle release of the acromial portion & an anterior half of the spinal portion
- ± anterior advancement of the released anterior half of the spinal portion

5. Gluteus Contracture: very rare



Operative Indications

- older than 6 years of age
- prominent snapping hip
- abduction contracture of larger than 20 degrees

Recommended Procedures

- release of the IT band for snapping hip
- release of the IT band & the lower deep portion of the gluteus maximus

6. Surgeries for quadriceps contracture at Nishitaga National Hospital (Sendai)

